Unexpected Subarachnoid Blood Following Labour Epidural Insertion

Dr Jonathan E. Dickerson CT3 and Dr Anna Cormack Consultant

Anaesthetics Department, Queen Elizabeth University Hospital, Glasgow

PRÉCIS

Lumbar epidural catheters are frequently inserted in labouring patients for analgesia. We describe an unusual presentation of subarachnoid haemorrhage following epidural insertion.

BACKGROUND

A 30yr old primigravida in spontaneous labour had an epidural sited for labour.

Insertion was not entirely straightforward with blood noted in the epidural catheter following the second attempt. The third attempt was successful and without immediate complications.

She later underwent an emergency caesarean section due to foetal concerns with an effective epidural 'top-up' using 2% lidocaine (titrated to 20mls with 1:200,000 adrenaline).

Delivery was straightforward and she was discharged home the next day without concerns.

Unfortunately, the patient presented three days later feeling generally unwell with a headache and abdominal pain. She was tachycardic, pyrexial and complained of a severe occipital headache.

A+B SpO2	A+B Respirations	C Blood Pressure	C Pulse	D Consciousness	E Temperature
96%	22	150/75mmHg	137	Alert	39.0°C

Her inflammatory markers were raised and blood cultures taken in A&E latterly grew E. coli.

White cells	Neutrophils	CRP	Haemoglobin
12.8×10^9/l	10.4×10^9/l	275mg/l	83g/l

CASE REPORT

On admission, she described her headache as being sudden onset and rapidly maximally severe (i.e., 'thunderclap'); it however lacked a postural component. There was no abnormal neurology and she had no photophobia.

A CT head and the. venogram was performed that did not demonstrate any abnormality, specifically no cerebral deep vein or sinus thromboses.

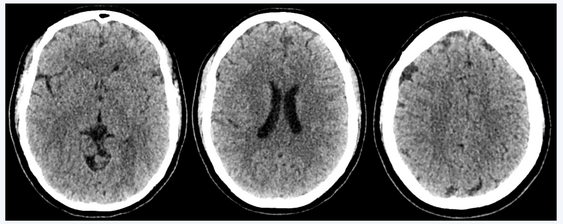

A CT abdomen at the time demonstrated typical postoperative findings with no focal collections, but a clinical diagnosis of endometritis was made in view of her overall presentation.

Of note, there was no indication of blood in the epidural space on the included spine, with only superficial subcutaneous blood visible at the level epidural anaesthesia was attempted.

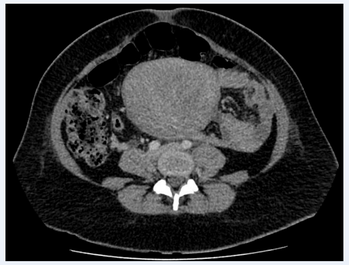

An LP was performed due to her fever and worsening neutrophilia. Whilst this did not show any signs of infection, her CSF appeared straw-coloured and demonstrated xanthochromia:

Bacteria	White cells	Oxy-haemoglobin	Bilirubin
Not seen	35/Cu.mm (Polymorphs 70%)	Increased	Increased

In view of this finding and her history, a CT intracranial angiogram was performed. This failed to demonstrate haemorrhage, aneurysm or malformation but did demonstrate intracranial hypotension.

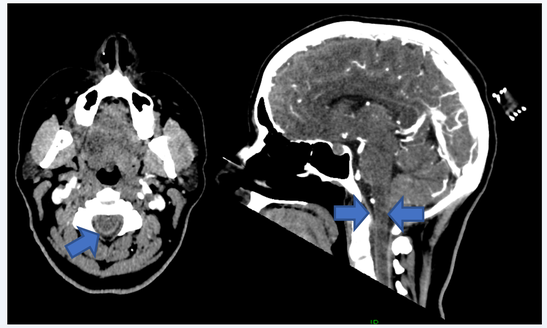

Extensive discussions with radiology, neuroradiology and neurosurgeons failed to reach consensus on the underlying cause(s) of her presentation and on if any follow-up should take place. Intervention was however felt unnecessary.

Her headache gradually improved, and she was discharged home. The patient has subsequently left Scotland but has been advised to discuss these events with her doctors should any future regional anaesthesia be needed.

DISCUSSION

Any vascular malformation of the spine could technically give rise to a subarachnoid haemorrhage and would not necessarily be demonstrated on CT.

As the intracranial imaging is suggestive of a low-pressure state and an epidural was inserted it is likely that a subdural puncture occurred. It remains unclear, despite imaging, if this is related to the subarachnoid or intrathecal blood demonstrated on LP. The degree of xanthochromia would be an unusual finding within the first week after an event and there remains scant previous evidence in the literature of subarachnoid haemorrhage following regional anaesthesia[1,2].

We suggest she had a non-aneurysmal subarachnoid bleed following epidural insertion, perhaps due to an underlying AV malformation.

It remains unclear to what extent any inadvertent subdural puncture has been contributory. A preceding occult CT-negative SAH remains an alternative possibility and we welcome discussion.

REFERENCES

1. Eggert SM, Eggers KA. Subarachnoid haemorrhage following spinal anaesthesia in an obstetric patient. British Journal of Anaesthesia 2001; 86(3): 4423-4

2. Singh V, Patel S, Singh K. Unexpected intrathecal haemorrhage following uncomplicated placement and removal of an epidural catheter. British Journal of Radiology Case Reports 2018; 4(3): 2017108.

Patient consent for publication was gained and can be provided.